

Percutaneous Gallbladder Stones Removal and Gallbladder Ablation: A Study of 10 Cases

MOHAMED M. RAWAS, FRCP(C)*, TALAL M. BAKHSH, FACHARZT**,
ADNAN A. MERDAD, FRCS(C)**, and ABDULWAHAB A.
NOORWALLI, PhD***

Department of Radiology, Department of General Surgery**, and
Department of Clinical Biochemistry***, Faculty of Medicine & Allied
Sciences, King Abdulaziz University, Jeddah, Saudi Arabia*

ABSTRACT. Percutaneous cholecystostomy (PC) and stone extraction from the gallbladder has been reported as a safe method for removal of gallstones. We report here our experience with percutaneous cholecystostomy (PC) and stone extraction on 10 patients. Four of these 10 patients had percutaneous cholecystostomy (PC) and stone extraction only: Two of them showed a stone-free gallbladder at 13 and 22 months of follow-up. The other 2 patients showed residual fragments seen at the immediate post-procedure follow-up. Three patients had gallstones' extraction and occlusion of the cystic duct by means of a catheter and absolute alcohol injection into the gallbladder lumen. All showed a gallbladder lumen free of stones at 15-28 months. Most importantly, 2 patients had gallstones' extraction followed by electrocoagulation of the cystic duct and absolute alcohol injection into the gallbladder. One patient had total gallbladder lumen ablation; the other patient had a gallbladder lumen with stone recurrence at 5 months of follow-up. The last patient had a patent cystic duct after electrocoagulation and no alcohol was injected. It is concluded that percutaneous cholecystostomy (PC) and gallstones' extraction with or without gallbladder lumen ablation may have a role in treatment of selected patients. Further investigation is needed in this regard.

Keywords: Percutaneous cholecystostomy, Gallbladder, Gallstones, Alcohol injection.

Correspondence & reprint requests to: Dr. Mohamed M. Rawas, P.O. Box 6615, Jeddah 21452, Saudi Arabia.
Accepted for publication: 5 September 1998. Received: 21 March 1998.

Introduction

The incidence of gallstones is approximately 15-20% in adults as shown by autopsies and clinical investigations cited in the literature^[1]. The standard treatment for gallstones have, for decades, been surgical intervention. Gallbladder surgery is effective and safe for otherwise, healthy individuals. Although recently, laparoscopic cholecystectomy has taken a major role in the management of cholelithiasis; gallstone patients tend to be older^[2]. Increased mortality and morbidity in older patients are well-known^[3,4].

The role of non-surgical methods as an effective, safe, and cost-efficient treatment of gallstones has been the subject of extensive research trials for the last two decades. This includes direct gallstone dissolution^[5-9] and extracorporeal shock wave lithotripsy of gallstones alone or in combination with oral bile acids^[10-19]. Percutaneous cholecystostomy (PC) and mechanical extraction of stones has been reported recently as a safe method for the removal of gallbladder stones^[20-24]. Mechanical extraction of gallstones has several advantages over chemical dissolution and shock wave lithotripsy including: 1) It allows the inclusion of calcified gallstones, 2) It dramatically shortens the time needed for the clearing of the gallbladder from stones, 3) It obviates the risk of leaving debris and small fragments which can form a nidus for recurrent stones.

We performed PC and gallstone extractions on 10 patients. In 4 patients, only stone extraction was done. In the other 6, attempts were made to occlude the cystic duct and ablate the gallbladder lumen using absolute alcohol. This clinical study was encouraged by our previous work and others on gallbladder ablation in experimental animals published earlier^[25,26]. The trial was also aimed at resolving difficulties and limitations of our earlier work on gallstones dissolution by MTBE^[9]. The results are discussed in relation to the management of PC.

Patients and Methods

Of the 10 patients, 8 were females and 2 were males. The age range was 24 to 66 years with a mean of 42.6 years. Six were Saudi and 4 were non-Saudi. All 10 patients had no increased risk for cholecystectomy but preferred non-surgical treatment. The details of the procedure are as follows: All patients signed an informed consent for the procedure, including cholecystectomy if indicated. The patient received 12 Biloptin capsules (cholecystogram contrast) orally 14 hours before the procedure. One hour before the procedure, the patient received sedation and prophylactic antibiotic cover. Under fluoroscopic guidance and local anaesthesia, a Mitty Pollack needle (Cook) was used to puncture the opacified gallbladder through a right transhepatic approach. Ultrasound-guided puncture of the gallbladder and contrast opacification was done if oral cholecystography failed to visualize the gallbladder. The entrance to the gallbladder was made at its attachment to the subhepatic surface. Using a 0.038-inch guide wire and a balloon dilator, a 32 French teflon sheath is inserted between the gallbladder lu-

men and the skin opening. The gallbladder was then washed with diluted contrast flushing out all stones from the gallbladder lumen (Fig. 1, plates 1,2,3). Gallstones larger than 1 cm in size (larger than sheath lumen) were crushed by a segura basket (4 wires, Meditech) and fragments washed out. This was followed by the insertion of an 8.3 French pigtail catheter into the gallbladder lumen. A final catheter cholecystogram was performed the next day before removing the catheter and terminating the procedure.

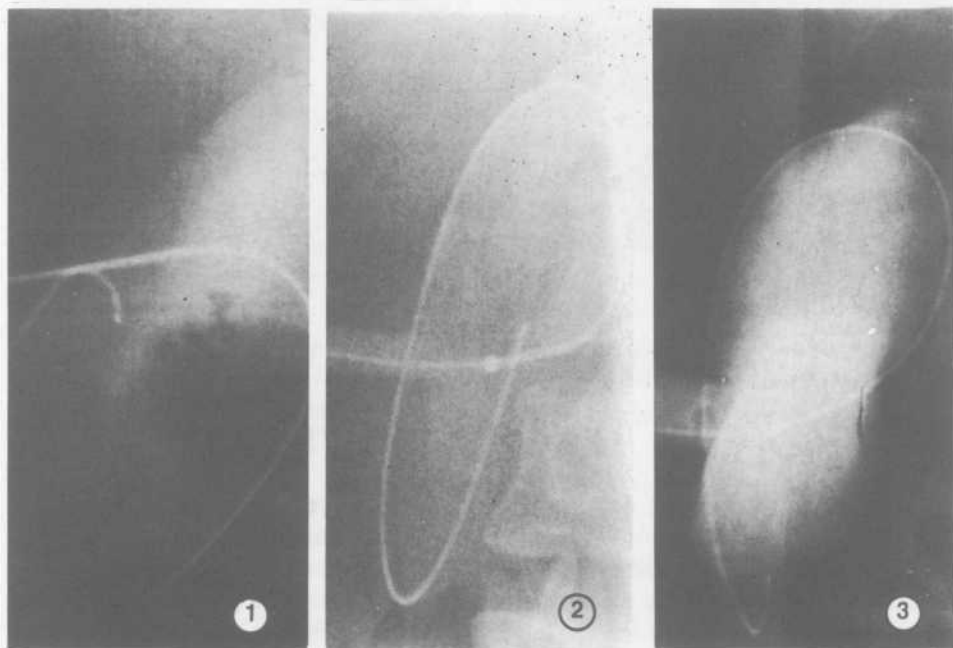


Fig. 1: Plate 1. The 18 gauge needle and an 0.038 J guide wire are in the gallbladder lumen. Plate 2. The facial balloon dilator between the gallbladder lumen and the skin opening is noted during inflation. Plate 3. The 32 French teflon sheath is in place with gallstones coming out through its lumen.

The first 4 patients were treated as described above. The next 3 patients had a catheter introduced into the gallbladder lumen (7 French Cobra Catheter, Cook). This catheter was advanced and wedged into the cystic duct lumen (Fig. 2, plates 1 & 2). After insuring total occlusion of the cystic duct and estimating the gallbladder volume by contrast medium, absolute alcohol was injected into the gallbladder through the balloon inflated Foley's catheter lumen and left in the gallbladder for 30 minutes and then removed. The alcohol volume equals the estimated gallbladder volume by contrast. The gallbladder was then washed repeatedly with normal saline (approximately five times). A final catheter cholecystogram was done. Both catheters were then connected separately to a closed system drainage bag. The Cobra catheter was removed after 24 hours. The Foley's catheter was removed after 48 hours.

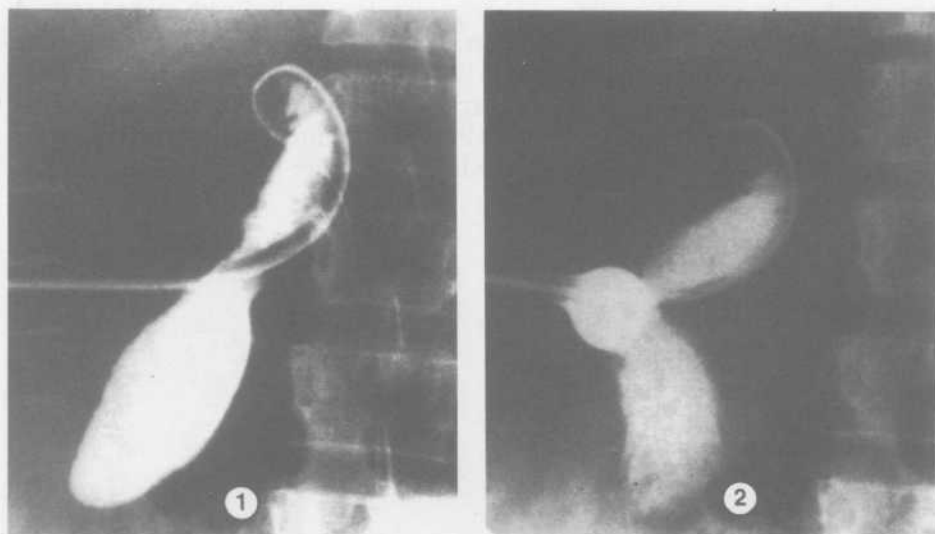


Fig. 2: Plate 1. The 7 French Cobra catheter is wedged in the cystic duct lumen over a guide wire that was advanced to the common bile duct. Plate 2. The gallbladder volume is measured by contrast injected through a Foley's catheter. Note the inflated balloon to prevent leakage at the puncture site.

In the last 3 patients, the occlusion of the cystic duct was carried out by an intraluminal electrocoagulation electrode advanced into the gallbladder lumen and then maneuvered and wedged into the cystic duct lumen (Fig. 3 plates 1 & 2). A unipolar electrode was used to deliver the electrocoagulation at 50 watts for 5 seconds and repeated five times. The pigtail catheter was left to the next day where a test of cystic duct occlusion was made by contrast injection. If the cystic duct was still patent, the electrocoagulation was repeated. Absolute alcohol was injected into the gallbladder and removed (Fig. 3, plate 2) as previously discussed. The pigtail catheter was left for 24 hours after the alcohol injection and then removed.

All patients were followed by ultrasound every 2 to 3 months. A post-procedure ultrasound examination was performed within two weeks. Liver function tests and complete blood count were done pre- and post-procedure in all patients.

Results

In all 10 patients studied the percutaneous transhepatic cholecystostomy, tract dilation, and the teflon sheath insertion were successful and uneventful. In the first 4 patients only stone extraction was performed (Table 1). Two patients were followed up to 13 and 22 months, respectively, and showed a stone-free gallbladder. Both patients revealed no biliary symptoms during the time of the follow-up. The third patient had one

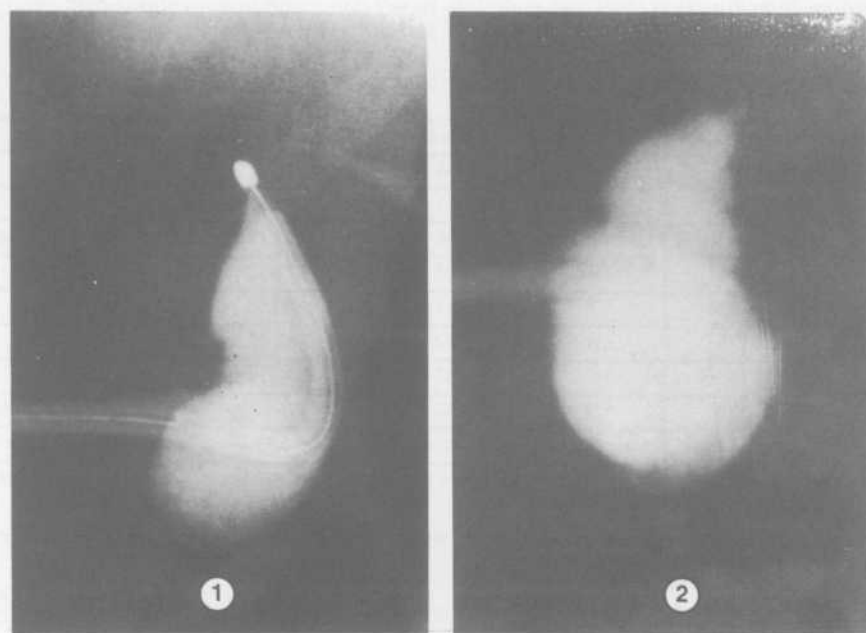


Fig. 3: Plate 1. The unipolar electrode is wedged in the proximal cystic duct lumen. Plate 2. Catheter cholecystogram showing occluded cystic duct.

of the stones larger than 10 mm in diameter and could not be removed through the 32 French sheath lumen (about 10 mm internal diameter). This stone was crushed by a basket and fragments were washed out. Unfortunately, one fragment was missed during the washout and was only discovered on the post-procedure ultrasound examination a week later. This patient was put on oral bile acids (chenodeoxycholic acid 500 mg and ursodeoxycholic acid 500 mg b.d. for one year). When the bile acid treatment was stopped, the fragment showed an increase in size. The patient was offered a cholecystectomy which she did not accept because she was asymptomatic. In the fourth patient, two tiny stones were missed in the gallbladder during the saline washout. This patient was also put on the same dose of oral bile acids like the previous patient. His stones disappeared after 16 months of treatment. The patient remained free of biliary stones and symptoms 28 months after the procedure.

The next 3 patients (Table 1) underwent the same procedure in addition to cystic duct occlusion by a catheter followed by attempted gallbladder ablation. They were followed up by serial ultrasound examination up to 20, 15, and 14 months, respectively. All showed a normal size gallbladder lumen as before ablation but no stone recurrence. No biliary symptoms were present during the follow-up period. The post-

procedure liver function tests and complete blood count showed no significant changes from pre-procedure tests.

TABLE 1. Details of patients studied.

Patient No.	Age/Sex	No. of Stones	Procedure	Follow-Up duration	Comments
1	58 F	14	M	13/12	Stone-free
2	41 F	2	M	22/12	Stone-free
3	66 F	6	M	22/12	Retained fragment
4	63 M	16	M	28/12	Retained stones
5	40 M	7	M + O + A	20/12	Stone-free
6	34 F	8	M + O + A	15/12	Stone-free
7	33 F	6	M + O + A	14/12	Stone-free
8	35 F	14	M + C + A	7/12	Ablated gallbladder
9	24 F	> 20	M + C + A	5/12	Retained stone
10	32 F	6	M + C	3/12	Patent cystic duct; stone-free

M - Mechanical stone extraction

O - Cystic duct occlusion by catheter

C - Endoluminal electrocoagulation of the cystic duct

A - Alcohol injection into the gallbladder

The last 3 patients (Table 1) had the same procedure as before except that the cystic duct was occluded using electrocoagulation. In one patient (No. 8), the gallbladder lumen was totally ablated as evidenced by ultrasound examination at seven months of follow-up (Fig. 4, plates 1 & 2).

The patient has no biliary symptoms and is still on regular follow-up. Patient no. 9 showed a gallbladder lumen by ultrasound examination at three weeks and at five months with a retained stone. Although she had no biliary symptoms, she accepted cholecystectomy. The gallbladder contained colorless mucoid material. The cystic duct showed an occluded lumen. The last patient had the electrocoagulation of the cystic duct repeated twice after stone extraction. The transcatheter cholecystogram showed a patent cystic duct after both attempts. Alcohol was not introduced into this gallbladder. Follow-up of this patient showed a stone-free gallbladder at three months. She was then lost for follow-up. The post-procedure liver function tests and complete blood count tests showed no significant changes from pre-procedure tests in all patients.

Discussion

The present study is part of a multi disciplinary research work on new concepts in non-surgical treatment of gallbladder stones. The research arms were the dissolution trial, dissolution plus extracorporeal shock wave lithotripsy trial, *in-vitro* gallstones dissolution experiments, and the mechanical gallstone extraction trial. One of the objectives of the percutaneous mechanical gallstone extraction trial was to evaluate the ef-

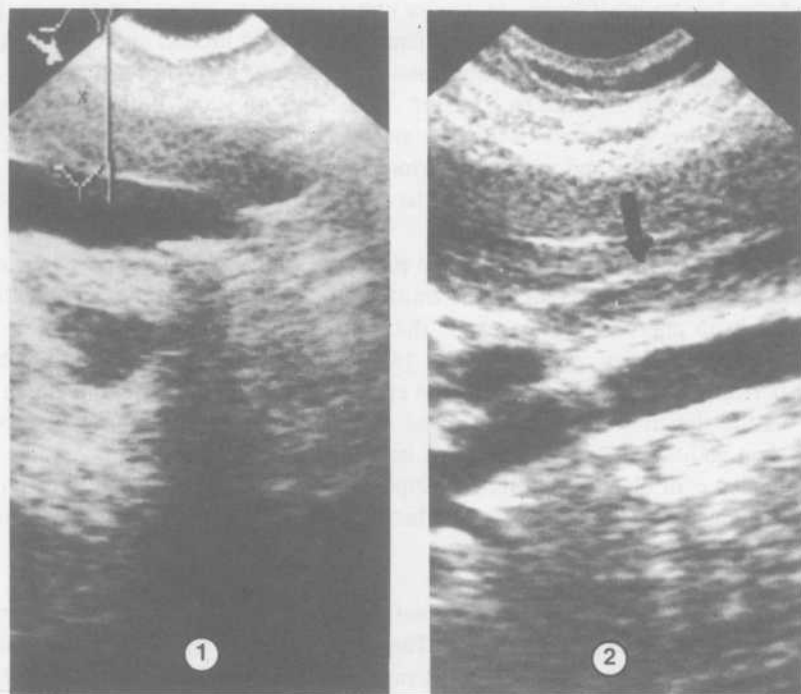


Fig: 4: Plate 1. Ultrasound appearance of the gallbladder before ablation (patient no. 8). Plate 2: The gall bladder region (arrow) is showing a 1 cm wide echogenic structure. No lumen was seen (patient no. 8).

iciency of the procedure. Attempts were made to achieve gallbladder ablation (chemical cholecystectomy).

The approach to the gallbladder by puncturing at its attachment to the subhepatic surface became a standard and acceptable safe procedure since our last published work on contact dissolution^[9]. This is in agreement with previous reports by Warren *et al*^[27] and Kerlan *et al*^[28]. The entrance to the gallbladder lumen at the attachment point to the liver surface helped in avoiding leakage of bile or contrast. Dilatation of the transhepatic tract and sheath insertion was easier and more effective in washing stones out of the gallbladder lumen. This is, in our opinion, due to limited ability of the gallbladder to move away from the puncture site. Because of bowel proximity to the fundus of the gallbladder, we do not prefer the subhepatic approach used by Cope *et al*^[29].

With regard to the procedure of mechanical extraction of stones from the gallbladder, the stone extraction was achieved by washing of the gallbladder using saline through the 32 French sheath. The sheath was not removed until contrast injection through its

lumen showed no residual stones. Catheter cholecystogram, as well, was done the next day in all patients. Nevertheless, in 3 patients stones were missed and only seen on the post-procedure ultrasound examination (patients no. 3, 4, and 9) (Table 1). In patient no. 3, fragmentation took place by a basket. In patients no. 4 and 9, the numerous small stones probably led to the loss of the tiny stones. Retrospectively, we think that transhepatic cholecystoscopy and removal of stones under direct vision and/or checking the gallbladder before sheath removal would have prevented the occurrence of the retained fragments and stones in these patients. The percutaneous cholecystoscopy either through the subhepatic or the transhepatic route has been used effectively by Leahy *et al*^[23] and Inui *et al*^[24]. Percutaneous transhepatic cholecystoscopy through the tract will also help in approaching the cystic duct through the guiding and wedging of the electrocoagulation probe. A two-channel 14 French flexible endoscope would be suitable for performing this task. A limitation exists in the size of the stone that can be extracted via the sheath (1 cm diameter) used in the procedure. If larger stones are to be tackled, then additional measures have to be added to fragment the stones, like basket ultrasound, laser, or electrohydraulic lithotripsy. This has been used effectively by previous investigators^[23,24]. The PC tract dilatation, sheath insertion, and stone extraction took an average of 60 minutes.

Only one patient (no. 1) could tolerate balloon dilatation of the transhepatic tract and sheath insertion under local anaesthesia. The other 9 patients needed heavy sedation by the attending anaesthetist (Midazolam 0.1 mg/kg IV, Fentanyl 2 mg/kg IV) at the time of the procedure. The cholecystostomy, cystic duct occlusion, and alcohol injection were all done under local anaesthesia and sedation (Pethidine 75 mg and Phenergan 50 mg IV). No complications were observed.

The presence of a gallbladder lumen gives a risk of stone reformation in all instances. So, in order to achieve permanent good results through PC, one has to permanently occlude the cystic duct and destroy the gallbladder mucosa. Absolute alcohol achieves mucosal destruction as we and others have shown in experimental animals^[25,26]. To occlude the cystic duct, we first selected to use the temporary blockage with catheters of suitable sizes. Spillage of alcohol into the biliary tree was excluded by test contrast injection into the gallbladder lumen until full expansion. The follow-up of these 3 patients showed at the beginning a small lumen with a markedly thickened gallbladder wall denoting inflammatory reaction. Later, however, the gallbladder again showed normal wall and lumen. Most likely, the gallbladder lumen was re-epithelialized from the cystic duct mucosa after the acute inflammatory reaction had subsided^[25].

Encouraged by recent publication on cystic duct occlusion using endoluminal electrocoagulation^[30-34], we performed this procedure on 3 patients. The coagulation resulted in cystic duct occlusion and gallbladder lumen ablation in one patient as shown by ultrasound examination. In patient no. 9, the retained stone seen at five months made the patient accepting the option of cholecystectomy. At operation, the gallbladder showed some mucoid material and the cystic duct was totally occluded. This patient added to our experience that electrocoagulation of the cystic duct, although it may not show early

occlusion by the acute inflammation, it will do so by fibrosis later on as previously mentioned^[33]. Becker *et al*^[33] used a bipolar catheter after cannulating the cystic duct by a Teromo guide wire. The above catheter was not commercially available and a unipolar electrode was used instead. The electrode was passed through a wedged catheter in the cystic duct.

Two of the patients studied were tested for immediate occlusion of the cystic duct and were positive. Becker *et al*^[33] had a one-week interval on the shortest time before cystic duct occlusion. An attempt to explain the non-occlusion of the cystic duct in patient no. 10 led us to think that electrocoagulation took place in the Hartmann's pouch of the gallbladder by not fully placing the electrode into the proximal end of the cystic duct. The control of the position of the electrode, therefore, is important to improve the results of cystic duct occlusion. Percutaneous cholecystoscopy will probably play an important role in this regard, as previously mentioned.

Further experience with the procedure is needed. In our opinion, percutaneous gallbladder stones extraction with or without lumen ablation may help in patients who are unable to have general anaesthesia, like old patients with cardiopulmonary disease. Intensive care patients, due to a wide range of medical diseases, may benefit from this procedure. The procedure may become an alternative to surgical options for patients refusing surgery.

In conclusion, percutaneous transhepatic mechanical extraction of gallbladder stones is an acceptable procedure in selected patients. Endoscopic examination of the gallbladder through the percutaneous tract may help in improving the procedure. It will probably shorten the time for stone removal, decreasing the risk of missing small stones or fragments, minimizing the amount of radiation, and making the cystic duct coagulation more precise. Temporary occlusion of the cystic duct by a catheter proved to be ineffective in ablating gallbladder lumen by alcohol. If permanent cystic duct occlusion is achieved by electrocoagulation, for example, then gallbladder lumen ablation (chemical cholecystectomy) by chemical destruction of the gallbladder mucosa using pure alcohol can be obtained. Gallbladder stones recurrence, therefore, will not be possible.

References

- [1] Herman RE. The spectrum of biliary stone disease. *Am J Surg* 1989; 158: 171-173.
- [2] Editorial. Gallstones, bile acids and the liver. *Lancet* 1989; 11: 249-251.
- [3] Greenburg AG, Salle RP, Garris JM, Peslein GW. Operative mortality in general surgery. *Am J Surg* 1982; 144: 22-28.
- [4] Gutman H, Heutsch AA, Nudelman IL, Reiss R. Cholecystectomy for octagenarians. *Dig Surg* 1988; 5: 189-193.
- [5] Walker JW. The removal of gallstones by ether solution. *Lancet* 1981; pp. 874-875.
- [6] Allen MJ, May GR, Borody TJ, LaRusso NF, Thistle JL. Methyl tertiary butyl ether rapidly dissolves gallstones in-vitro and in-vivo. *Hepatology* 1983; 3: 809.
- [7] Allen MJ, Borody TJ, Bugliosi TF, May GR, LaRusso NF, Thistle JL. Cholelitholysis using methyl tertiary butyl ether. *Gastroenterol* 1985; 88(1): 122-125.

- [8] Thistle JL, May GR, Bender CE, Williams HJ, LeRoy AJ, Nelson PE, Peine CJ, Petersen BT, McCullough JE. Dissolution of cholesterol gallbladder stones by methyl tert-butyl ether administered by percutaneous transhepatic catheter. *N Engl J Med* 1989; 320(10): 633-639.
- [9] Rawas M, Bakhsh T, Noorwall A, Merdad A. Percutaneous cholecystostomy and gallstones dissolution by MTBE. *Saudi Med J* 1990; 11(1): 25-28.
- [10] Sackmann M, Dellus M, Sauerbruch T, Holl J, Weber W, Ippisch E, Hagelauer U, Wess O, Hepp W, Brendel W. Shock-wave lithotripsy of gallbladder stones. *N Engl J Med* 1988; 318(7): 393-397.
- [11] Sackmann M, Weber W, Dellus M, Holl J, Hagelauer U, Sauerbruch T, Brendel W, Paumgartner G. Extracorporeal shock-wave lithotripsy of gallstones without general anaesthesia: first clinical experience. *Ann Intern Med* 1987; 107(3): 347-348.
- [12] Sauerbruch T, Dellus M, Paumgartner G, Holl J, Wess O, Weber W, Hepp W, Brendel W. Fragmentation of gallstones by extracorporeal shock waves. *N Engl J Med* 1986; 314(13): 818-822.
- [13] Brendel W, Enders G. Shock waves for gallstones: animal studies [letter]. *Lancet* 1983; 1(8332): 1054.
- [14] Hofman AF, Greenbergem N, Babayan K. Report of the United States cooperative study of the treatment of gallstones with lithotripsy. *Dig Dis Sci* 1982; 34: 1071-1072.
- [15] Malt RA, Rothschild JG, Holbrook RF, Mueller PR, Simeone JF, Latta WB, Kimball WR, Reinhold RB. Extracorporeal shock-wave lithotripsy of gallstones: Boston experience with the Dormier MPL 9000 lithotripter. *Am J Surg* 1989; 158(3): 192-193.
- [16] Vanderpool D, Jones RC, O'Leary JP, Hamilton JK. Biliary lithotripsy. *Am J Surg* 1989; 158(3) 194-197.
- [17] Sauerbruch T. Gallstone lithotripsy by extracorporeal shock waves. *Am J Surg* 1989; 158: 188-191.
- [18] Hutton SW, Sievert CE Jr., Vennes JA, Shafer RB, Duane WC. Spontaneous passage of glass beads from the canine gallbladder: facilitation by sphincterectomy. *Gastroenterol* 1988; 94(4): 1031-1035.
- [19] Sackmann M, Sauerbruch T, Dellus M, Holl J, Weber W, Hagelauer U, Hepp W, Brendel W, Daumgartner G. Gallstones lithotripsy: the Munich experience. *Proceedings of the Meeting of the College of Surgeons, Milano*. 1988.
- [20] Gibney RG, Fache JS, Becker CD, Nichols DM, Cooperberg PL, Stoller JL, Burhenne HJ. Combined surgical and radiologic intervention for complicated cholelithiasis in high-risk patients. *Radiology* 1987; 165(3): 715-719.
- [21] Picus D, Marx MV, Hicks ME, Lang EV, Edmundowicz SA. Percutaneous cholecystolithotomy: preliminary experience and technical considerations. *Radiology* 1989; 173(2): 487-491.
- [22] Hruby W, Stackl W, Urban M, Armbruster C, Marberger M. Percutaneous endoscopic cholecystolithotripsy. Work in progress. *Radiology* 1989; 173(2): 477-479.
- [23] Leahy AL, Darzi AW, Murchan PM, O'Gorman S, Hamilton S, Tanner WA, Keane FB. A safe new procedure for high-risk patients with symptomatic gallstones. *Br J Surg* 1991; 78(11): 1319-1320.
- [24] Inui K, Nakazawa S, Yoshino J, Yamao K, Naito Y, Kimoto E, Asai T. Percutaneous cholecystoscopy. *Endoscopy* 1989; 21(suppl 1): 361-364.
- [25] Leahy AL, McCollum PT, O'Gorman S, Darzi A, Marks P, Kay E, Tanner WA, Keane FB. Cystic duct obliteration and gallbladder mucosal destruction: a feasible alternative to cholecystectomy. *Br J Surg* 1991; 78(1): 1321-1324.
- [26] Bakhsh T, Nasif O, Noorwall M, Rawas M. Non-surgical ablation of the gallbladder: an animal study. *Saudi Med J* 1993; 14(2): 138-141.
- [27] Warren LP, Kadir S, Dunnick WR. Percutaneous cholecystectomy: anatomic consideration. *Radiol* 1988; 168: 615-616.
- [28] Kerlan Jr R, LaBerge JM, Ring EJ. Percutaneous cholecystolithotomy: preliminary experience. *Radiol* 1985; 157: 653-656.
- [29] Cope C, Burke D, Meranza SG. Percutaneous extraction of gallstones in 20 patients. *Radiology* 1990; 176: 19-24.
- [30] Getrajdman GI, O'Toole K, Laffey KJ, Martin EC. Cystic duct occlusion and transcatheter sclerosis of the gallbladder in the rabbit. *Invest Radiol* 1986; 21(5): 400-403.
- [31] Becker CD, Quenville NF, Burhenne HJ. Long-term occlusion of the porcine cystic duct by means

- of endoluminal radio-frequency electrocoagulation. *Radiol* 1988; 167(1): 63-68.
- [32] Becker CD, Quenville NF, Burhenne HJ. Gallbladder ablation through radiologic intervention: an experimental alternative to cholecystectomy. *Radiology* 1989; 171(1): 235-240.
- [33] Becker CD, Fache SJ, Malone DE, Stoller JL, Burhenne HJ. Ablation of the cystic duct and gallbladder: clinical observations. *Radiology* 1990; 176(3): 687-690.
- [34] Girard MJ, Saini S, Mueller RR, Flotte TJ, Startiz M, Domankevitz Y, Ferrucci JT, Nishioka N. Percutaneous obliteration of the cystic duct with a Holmium Yttrium-aluminum-garnet laser: results of in-vitro and animal experiments. *AJR Am J Roentgenol* 1992 Nov; 159(5): 991-995.

استخراج حصوات المرارة الغير تنظيري أو جراحي وملاشاة التجويف المراري: دراسة ١٠ حالات

محمد رواس*، طلال بخش**، هندان مرداد**، و عبدالوهاب نورولي***
قسم الأشعة*، قسم الجراحة العامة**، وقسم الكيمياء الحيوية السريرية***،
كلية الطب والعلوم الطبية، جامعة الملك عبدالعزيز،
جدة، المملكة العربية السعودية

المستخلص. استخراج حصوات المرارة الغير جراحي معروف وأمن. هذه الدراسة تسجل خبرتنا لعشرة مرضى أجريت عليهم عملية الاستخراج. أربعة مرضى تم استخراج الحصوات منهم فقط. وأظهرت المتابعة أن المرارة خالية من الحصوات بعد ١٢-٢٢ شهرا لإثنين منهم أما الإثنين الأخران كان لديهما مخلفات حصوية بعد الاستخراج مباشرة. ثلاثة مرضى تم استخراج الحصوات وقفل قناة الكيس المراري بواسطة قسطرة وحقن كحول في التجويف المراري وأظهرت المتابعة وجود تجويف مراري خالي من الحصوات بعد ١٤-٢٠ شهراً. مريضتين تم استخراج الحصوات وقفل الكيس المراري بواسطة الكي الكهربائي وحقن كحول في التجويف المراري، أظهرت المتابعة تلاشي التجويف المراري في أحدهما، ووجود تجويف مراري يحتوي على حصوة في الآخر. في المريض الأخير كان هناك قناة كيس مراري سالكا بعد محاولة القفل بالكي عدة مرات ولم يتم حقن الكحول. نستخلص أن استخراج حصوة المرارة الغير جراحي تلاشى التجويف المراري قد يكون خياراً لإزالة حصوات المرارة في حالات مرضية معينة. كما أن هناك حاجة لمزيد من الأبحاث في هذا المجال.